

# General Body and Directional Terms

## Course

Anatomy &  
Physiology

## Unit I

Orientation to the  
Human Body

## Essential Question

What common  
terminology is  
used to describe  
human  
anatomy?

## TEKS

130.206 (c)  
2A  
6A, 6B  
10A

## Prior Student Learning

None

## Estimated time

2-4 hours

## Rationale

Healthcare professionals must have a comprehensive medical vocabulary in order to communicate effectively with other health professionals.

## Objectives

Upon completion of this lesson, the learner should be able to:

- define and decipher common terms associated with the structural organization of the body;
- identify the body cavities and distinguish the organs contained within those cavities; and
- list and define the terms related to positions, directions and planes of the body.

## Engage

Place several markings on a student volunteer's body. Have three other students write down how they would describe where the marks are located on the student volunteer. Then have each of the three students read aloud what they have written. Explain that by using medical terms to describe the locations of the marks, we can be more exact and this will help whomever is reading the report understand the true location of injuries, anomalies or incisions.

## Key Points

- I. Branches of Science that study the human body
  - a. Anatomy
    1. Means "cutting apart" (dissection)
    2. Study of the body and the relationships of its parts to each other
    3. Dissection is used to study the structure of the human body
  - b. Biology - Study of all forms of life and living things
  - c. Embryology
    1. Study of the origin and development of an organism
    2. Covers from 2<sup>nd</sup> to the 8<sup>th</sup> week after conception, the *embryonic state*
    3. After eight weeks, the developing organism is known as a *fetus*.
  - d. Histology
    1. Study of the body microscopically
    2. Studies the minute structures and their composition, plus the functions of normal cells, tissue and organs.
  - e. Pathology
    1. Study of the changes in the human body which are caused

- by disease
- 2. Study changes due to disease that alter the function of the body
- f. Physiology - Studies the normal activity and functions of the body

## II. Body in General

- a. Cells are the basic unit of life
- b. Cells that perform similar functions join together, or group together, to form tissue.
- c. Groups of different types of tissue join together to form an organ
- d. Groups of organs work together to perform a complex function, for a body system
- e. Trillions of cells that vary in size and shape according to their purpose or function
- f. Specialized cells are responsible for the functions of growth, secretions, excretions, nutrition, and reproduction
- g. Mechanical, chemical and nervous stimulation activate the cells

## III. Cells

- a. Epithelial cells
  - 1. Skin cells
  - 2. May be square and flat
- b. Fat cells - contain large vacant spaces for fat storage
- c. Muscle cells - long and slender
- d. Nerve cells - may be long and have fingerlike extensions, which carry impulses

## IV. Tissues

- a. Connective tissue
  - 1. Supports and encases body structures.
  - 2. Most widespread kind of tissue throughout the body
  - 3. Holds organs in place and connects body parts to each other
  - 4. Main types of connective tissue:
    - (a) Bone that supports the body
    - (b) Cartilage which is firm but bendable
    - (c) Dense fibrous: makes up the tendons and ligaments
    - (d) Loose that connects adjoining structures
    - (e) Adipose that pads and protects, stores fat, and insulates the body against heat loss
- b. Epithelial tissue
  - 1. Found in the skin and in the lining of blood vessels
  - 2. Makes up the outer covering of external and internal body surfaces and the lining of the digestive, respiratory, and

- urinary tracts
- c. Muscle tissue
  1. Provides movement
  2. The main function is to contract
- d. Nerve tissue
  1. Conducts impulses to and from the brain
  2. Is composed of nerve cells called neurons
  3. Needs more oxygen and nutrients than any other body tissue

## V. Organs

- a. When two or more kinds of tissue work together to perform a specific function, you have an organ
- b. Although organs act as units, they do not function alone
- c. Several organs join together to form a system and perform a body function
- d. Each system has a special function

## VI. Systems

- a. Cardiovascular system
  1. Includes the heart and blood vessels
  2. Carries the blood throughout the body
- b. Digestive or gastrointestinal system
  1. Includes the mouth, esophagus, stomach, and the small and large intestines
  2. Digests and absorbs food and excretes waste
- c. Endocrine system
  1. Made up of a variety of glands
  2. Manufactures and distributes hormones
- d. Integumentary system
  1. Includes the hair, skin, nails, sweat glands and oil glands
  2. Helps protect the body
- e. Lymphatic system
  1. Works with the cardiovascular system
  2. Helps protect the body against disease-causing organisms
- f. Musculoskeletal system
  1. Composed of bones, muscles, tendons and ligaments
  2. Provides the framework for the body
  3. Supports organs
  4. Permits movement in the body
- g. Reproductive system
  1. Includes the uterus, ovaries, testes, and prostate
  2. Provides for reproduction
- h. Respiratory system
  1. Includes the trachea, lungs, and bronchi
  2. Provides for the exchange of gases
  3. Absorbs oxygen

4. Expels carbon dioxide
- i. Sensory or special senses system
  1. Made up of the eyes, ears, nose, mouth, skin and nerves
  2. Acts as the body's external perception/alarm system by letting in light, sound, taste and touch (both pleasure and pain)
- j. Nervous System
  1. Brain, spinal cord and nerves
  2. Allows the body to act and respond
- k. Urinary system
  1. Manufactures and excretes urine
  2. Includes the kidneys, ureters, urinary bladder, and urethra

## VII. Cavities of the Body

- a. Abdominal cavity
  1. Contains the stomach, intestines, liver, spleen, gallbladder, pancreas, ureters, and kidneys
  2. Ventral body cavity (located on the front of the body)
- b. Cranial cavity
  1. The cavity inside the skull, or the cranium
  2. Space within the skull containing the brain
  3. Cranial means "pertaining to the skull".
  4. Dorsal body cavities (located on the back part of the body)
- c. Pelvic cavity
  1. Contains the urinary bladder, urethra, uterus and vagina in the female, part of the large intestine and the rectum
  2. Ventral body cavity (located on the front of the body)
  3. Space below the abdomen
- d. Spinal cavity
  1. Consist of the spinal column connecting to the cranial cavity
  2. Space within the spinal column (backbone) containing the spinal cord
  3. Dorsal body cavities (located on the back part of the body)
- e. Thoracic or chest cavity
  1. Contains the esophagus, trachea, lungs, heart and aorta
  2. Can be divided into two smaller areas
    - (a) The pleural cavity surrounds the lungs
    - (b) The mediastinum is the area between the lungs, containing the heart, aorta, trachea, esophagus and thymus gland
  3. Ventral body cavity (located on the front of the body)
- f. Pleural cavity
  1. Space around each lung

## VIII. Roots of Structures

Root	What it Means	Example term	What it Means
Cyt/o	Cell	Cytology	Study of cells
Epitheli/o	Epithelium	Epithelioma	Tumor of the skin
Fibr/o	Fibrous	Fibrosis	Condition of the fibrous tissue
Hist/o	Tissue	Histologist	Physician who studies tissue
Lip/o	Fat	Liposuction	Removal of fat cells by suction
Myo	Muscle	Myositis	Enlargement of an organ
Neur/o	Nerve	Neuropathy	Condition of the nerve
Organ/o	Organ	Organomegaly	Enlargement of an organ
Viscer/o	Internal organs	Viscera	Internal organs

#### IX. Structural Suffixes

Suffix	What it Means	Example term	What it Means
-cyte	Cell	Erythrocyte	Red blood cell
-gen	Agent that causes	Carcinogen	Agent causing cancer
-genic	Producing	Carcinogenic	Has cancer-causing properties
-oma	Tumor or swelling	Myoma	Tumor in the muscle
-osis	Abnormal condition	Cytosis	Abnormal condition of cells
-pathy	Disease	Neuropathy	A disease of the nerves
-plasm	Growth or formation	Neoplasm	A new growth
-sarcoma	Malignant tumor	Myosarcoma	Malignant muscle tumor

#### X. Directional Terms

- a. Used to pinpoint or specifically locate an area on the body.
- b. Anatomical position is the body standing, arms at each side, with palms facing forward and the feet side by side
- c. Anatomical plane
  1. An imaginary flat plate or field
  2. Provide further division of the body, to identify a specific location or area
- d. Frontal or coronal plane
  1. A vertical plane dividing the body into anterior and posterior

- portions
- 2. Anterior means front
- 3. Posterior refers to the back
- e. Mid-sagittal plane
  - 1. A horizontal plane
  - 2. Divides the body into right and left halves at the body's midpoint
- f. Sagittal plane
  - 1. A vertical plane
  - 2. Passes from front to back
  - 3. Divides the body into right and left sides
- g. Transverse plane
  - 1. A horizontal (cross-section) plane, parallel to the ground and through the waistline
  - 2. Divides the body into upper and lower halves
- h. Ventral
  - 1. Anterior
  - 2. Refers to the front of the body
- i. Dorsal
  - 1. Posterior
  - 2. Refers to the back of the body
- j. Cephalad
  - 1. Above the waistline
  - 2. "head" or "upward"
  - 3. Superior – "above"
- k. Caudal
  - 1. Below the waistline
  - 2. Inferior, below
- l. Superior and inferior
  - 1. Also used to describe body parts in relation to one another in general
- m. Lateral - sides of the body
- n. Medial – refers to the middle
- o. Distal – away from the point of origin
  - 1. The foot would be the distal portion of the leg
- p. Proximal – refers to 'nearest the point of origin', close proximity
  - 1. The upper thigh would be the proximal portion of the leg
- q. Ipsilateral
  - 1. Pertains to one side
- r. Mediolateral
  - 1. Pertaining to the middle and one side

#### XI. Root words that pertain to directional terms

Root word	What it means
Anter/o	Front
Caud/o	Tail or downward
Cephal/o	Head or upward
Dist/o	Away from (distant) the point of origin
Dors/o	Back
Infer/o	Below
Later/o	Side
Medi/o	Middle
Poster/o	Back or behind
Proxim/o	Near to (proximity) the point of origin
Super/o	Above
Ventr/o	Front or belly

## XII. Regions of the body

- a. Anatomical divisions of the abdomen
- b. Used to describe the regions in which organs and structures are found
- c. Used to diagnose abdominal problems with greater accuracy
  1. Hypochondriac region
    - (a) Upper lateral regions beneath the ribs
  2. Epigastric region
    - (a) Region of the stomach
  3. Lumbar region
    - (a) Two middle lateral regions
  4. Umbilical region
    - (a) Region of the navel or umbilicus
  5. Inguinal (iliac) region
    - (a) Lower lateral regions
  6. Hypogastric region
    - (a) Lower middle region, below the umbilicus

## XIII. Quadrants

- a. Right upper quadrant
  1. **RUQ**
  2. Contains the right lobe of the liver, gallbladder, and parts of the small and large intestines.
- b. Left upper quadrant
  1. **LUQ**
  2. Contains the left lobe of the liver, stomach, pancreas, spleen, and parts of the small and large intestines
- c. Right lower quadrant
  1. **RLQ**
  2. Contains parts of the small and large intestines, appendix, right ureters, right ovary, and fallopian tube.
- d. Left lower quadrant

1. LLQ

2. Contains parts of the small and large intestines, left ureters, left ovary, and fallopian tube

XIV. Divisions of the back

Division	Abbreviation	Location
Cervical	C	Neck region. There are 7 cervical vertebrae (C1-C7).
Thoracic	T or D (D = dorsal)	Chest region. There are 12 thoracic vertebrae (T1-T12). Each bone is joined to a rib
Lumbar	L	Loin or flank region (between the ribs and the hip bone). There are 5 lumbar vertebrae (L1-L5).
Sacral	D	Five bones (S1-S5) are fused to form one bone, the sacrum.
Coccygeal	(none)	The coccyx (tailbone) is a small bone composed of 4 fused pieces.

XV. Other body regions

Region	Where it is
Auricular region	Around the ears
Axillary	Axillae (armpits)
Buccal	Cheeks of the face
Clavicular	On each side of the sternum (breastbone)
Infraorbital	Below the eyes
Infrascapular	On each side of the chest down to the last rib
Lumbar	Below the infrascapular area
Mammary	Breast area
Mental	Region of the chin
Orbital	Around the eyes
Pubic	Above the hypogastric region (above the pubis)
Sacral	Area over the sacrum
Sternal	Over the sternum
Submental	Below the chin
Supraclavicular	Above the clavicles

XVI. Positions

- a. Erect – a standing position
- b. Lateral recumbent – lying on left side with right thigh and knee drawn up to chest
- c. Prone – lying face down
- d. Supine – lying flat on your back

- e. Sims' position
  - 1. Semi-prone side position
  - 2. Lying on the left side with the right thigh and knee sharply flexed; left leg straight
  - 3. The lower arm (left) is behind the person
  - 4. Pillow is under the person's head and shoulder
  - 5. Usually not comfortable for older persons
- f. Fowler's position
  - 1. Semi-sitting
  - 2. The head of the bed is raised between 45 and 60 degrees
  - 3. Spine is straight
  - 4. Head is supported with a small pillow

### **Activity**

- I. In pairs, create a stick-like figure, with a head, trunk, arms, and legs using play dough. As the terms are discussed, the student will use a toothpick to designate the area. After all the terms are discussed, cut the figure into the planes.
- II. In pairs, identify the following areas on partner:
  - Area distal to the knee.
  - Area proximal to the elbow.
  - Lateral to the big toe.
  - Anterior side of the body.
  - Posterior side of the body.
  - Area that is medial to the shoulder.
  - Area that is superior to the lungs.
  - Area that is inferior to the heart.
- III. Complete Body and Directional Terms Worksheet.
- IV. Complete Color the Cavities and Color the Abdominal Regions activity.
- V. Complete the Body Planes and Directions activity.
- VI. Develop a Short Story describing best date or worst nightmare using anatomical terms.
- VII. Show students copies of CT-scans and quiz them on which body plane is being used.

### **Assessment**

Successful completion of the activities  
 Writing Rubric  
 Body Orientation Quiz and Key

### **Materials**

Assorted colors of play dough  
 Crayons  
 Colored toothpicks  
 Paper plates  
 Rulers  
 Bananas

Permanent markers

<http://www.ama-assn.org/ama/pub/physician-resources/patient-education-materials/atlas-of-human-body.shtml> - atlas of the human body

Data projector

Computer

Utah State Office of Education, (2005). *Medical Anatomy and Physiology Teacher Resource CD*. Utah.

### **Accommodations for Learning Differences**

For reinforcement, the student will practice terms using flash cards.

For enrichment, the student will choose 20 general body and directional terms and create a crossword puzzle

### **National and State Education Standards**

#### **National Healthcare Foundation Standards and Accountability Criteria:**

Foundation Standard 2: Communications

2.21 Use roots, prefixes, and suffixes to communicate information

2.22 Use medical abbreviations to communicate information

### **TEKS**

130.206 (c)(2)(A) know the definition of science and understand that it has limitations, as specified in subsection (b)(2) of this section;

130.206 (c)(6)(A) investigate and describe the integration of the chemical and physical processes, including equilibrium, temperature, pH balance, chemical reactions, passive transport, active transport, and biofeedback, that contribute to homeostasis;

130.206 (c)(6)(B) determine the consequences of the failure to maintain homeostasis; and

130.206(c)(10)(A) analyze the relationships between the anatomical structures and physiological functions of systems, including the integumentary, nervous, skeletal, musculoskeletal, cardiovascular, respiratory, gastrointestinal, endocrine, and reproductive.

### **Texas College and Career Readiness Standards**

#### *English and Language Arts*

Understand new vocabulary and concepts and use them accurately in reading, speaking, and writing

1. Identify new words and concepts acquired through study of their relationships to other words and concepts
2. Apply knowledge of roots and suffixes to infer the meanings of new words
3. Use reference guides to confirm the meanings of new words or concepts

#### *Cross-Disciplinary Standards*

I. Key Cognitive Skills

D. Academic Behavior:

1. Self-monitor learning needs and seek assistance when needed;
3. Strive for accuracy and precision;
4. Persevere to complete and master task

E. Work habits:

1. Work independently
2. Work collaboratively

II. Foundation Skills

A.

2. Use a variety of strategies to understand the meaning of new words
4. Identify the key information and supporting details

## Body and Directional Terms

Root	What it Means	Example term	What it Means
Cyt/o		Cytology	
Epitheli/o		Epithelioma	
Fibr/o		Fibrosis	
Hist/o		Histologist	
Lip/o		Liposuction	
Myo		Myositis	
Neur/o		Neuropathy	
Organ/o		Organomegaly	
Viscer/o		Viscera	

Root word	What it means
Anter/o	
Caud/o	
Cephal/o	
Dist/o	
Dors/o	
Infer/o	
Later/o	
Medi/o	
Poster/o	
Proxim/o	
Super/o	
Ventr/o	

Suffix	What it Means	Example term	What it Means
-cyte		Erythrocyte	
-gen		Carcinogen	
-genic		Carcinogenic	
-oma		Myoma	
-osis		Cytosis	
-pathy		Neuropathy	
-plasm		Neoplasm	
-sarcoma		Myosarcoma	

Division	Abbreviation	Location
Cervical	C	
Thoracic	T or D (D = dorsal)	
Lumbar	L	
Sacral	D	

## Medical Terminology

## Body and Directional Terms

Region	Where it is
Auricular region	
Axillary	
Buccal	
Clavicular	
Infraorbital	
Infrascapular	
Lumbar	
Mammary	
Mental	
Orbital	
Pubic	
Sacral	
Sternal	
Submental	
Supraclavicular	

afferent	
efferent	
anterior	
posterior	
central	
deep	
superficial	
distal	
proximal	

inferior	
superior	
lateral	
medial	
supine	
prone	

Frontal plane	
Sagittal plane	
Transverse plane	

**KEY - Medical Terminology**  
Body and Directional Terms

Root	What it Means	Example term	What it Means
Cyt/o	Cell	Cytology	Study of cells
Epitheli/o	Epithelium	Epithelioma	Tumor of the skin
Fibr/o	Fibrous	Fibrosis	Condition of the fibrous tissue
Hist/o	Tissue	Histologist	Physician who studies tissue
Lip/o	Fat	Liposuction	Removal of fat cells by suction
Myo	Muscle	Myositis	Enlargement of an organ
Neur/o	Nerve	Neuropathy	Condition of the nerve
Organ/o	Organ	Organomegaly	Enlargement of an organ
Viscer/o	Internal organs	Viscera	Internal organs

Root word	What it means
Anter/o	Front
Caud/o	Tail or downward
Cephal/o	Head or upward
Dist/o	Away from (distant) the point of origin
Dors/o	Back
Infer/o	Below
Later/o	Side
Medi/o	Middle
Poster/o	Back or behind
Proxim/o	Near to (proximity) the point of origin
Super/o	Above
Ventr/o	Front or belly

Suffix	What it Means	Example term	What it Means
-cyte	Cell	Erythrocyte	Red blood cell
-gen	Agent that causes	Carcinogen	Agent causing cancer
-genic	Producing	Carcinogenic	Has cancer-causing properties
-oma	Tumor or swelling	Myoma	Tumor in the muscle
-osis	Abnormal condition	Cytosis	Abnormal condition of cells
-pathy	Disease	Neuropathy	A disease of the nerves
-plasm	Growth or formation	Neoplasm	A new growth
-sarcoma	Malignant tumor	Myosarcoma	Malignant muscle tumor

Division	Abbreviation	Location
Cervical	C	Neck region. There are 7 cervical vertebrae (C1-C7).
Thoracic	T or D (D = dorsal)	Chest region. There are 12 thoracic vertebrae (T1-T12). Each bone is joined to a rib
Lumbar	L	Loin or flank region (between the ribs and the hip bone). There are 5 lumbar vertebrae (L1-L5).
Sacral	D	Five bones (S1-S5) are fused to form one bone, the sacrum.
Coccygeal	(none)	The coccyx (tailbone) is a small bone composed of 4 fused pieces.

Region	Where it is
Auricular region	Around the ears
Axillary	Axillae (armpits)
Buccal	Cheeks of the face
Clavicular	On each side of the sternum (breastbone)
Infraorbital	Below the eyes
Infrascapular	On each side of the chest down to the last rib
Lumbar	Below the infrascapular area
Mammary	Breast area
Mental	Region of the chin
Orbital	Around the eyes
Pubic	Above the hypogastric region (above the pubis)
Sacral	Area over the sacrum
Sternal	Over the sternum
Submental	Below the chin
Supraclavicular	Above the clavicles

afferent	Conducting toward a structure.
efferent	Conducting away from a structure.
anterior	Front of the body ( <u>ventral</u> ).
posterior	Back of the body ( <u>dorsal</u> ).
central	Pertaining to the center.
deep	Away from the surface.
superficial	Near the surface.
distal	Away from the beginning of a structure; away from the center.
proximal	Pertaining to the beginning of a structure

inferior	Away from the head; below another structure ( <u>caudal</u> ).
superior	Toward the head; above another structure ( <u>cephalic</u> ).
lateral	Pertaining to the side.
medial	Pertaining to the middle.
supine	Lying on the back
prone	Lying on the belly

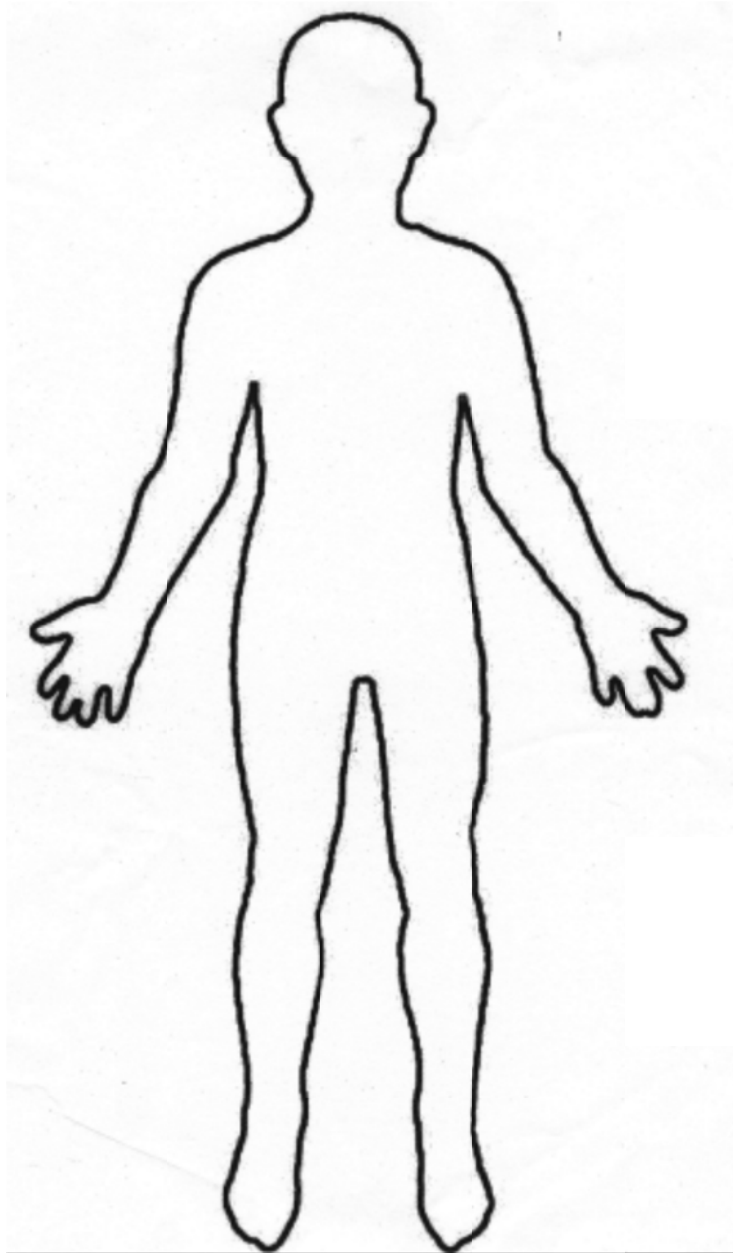
Frontal plane	Vertical plane dividing the body or structure into an anterior and posterior portion.
Sagittal plane	Vertical plane dividing the body or structure into right and left portions.
Transverse plane	Horizontal plane dividing the body or structure into upper and lower portions.

## Color the Cavities

Using a diagram of the human body, label and color code each of the following.

Ventral Cavity  
Thoracic Cavity  
Pleural Cavities  
Pelvic Cavity

Mediastinum  
Pericardial Cavity  
Abdominopelvic Cavity  
Abdominal Cavity

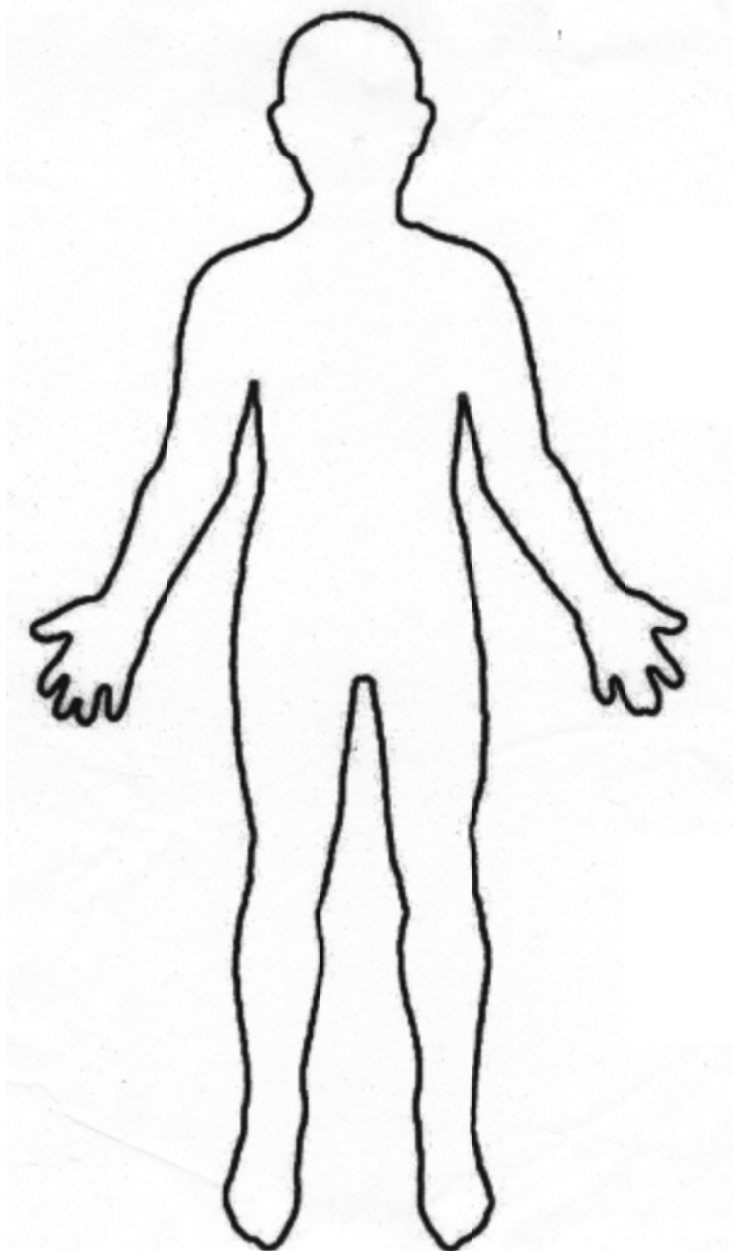


## Color the Cavities

Using a diagram of the human body, label and color code each of the following.

Dorsal cavity  
Spinal (Vertebral) Cavity

Cranial Cavity

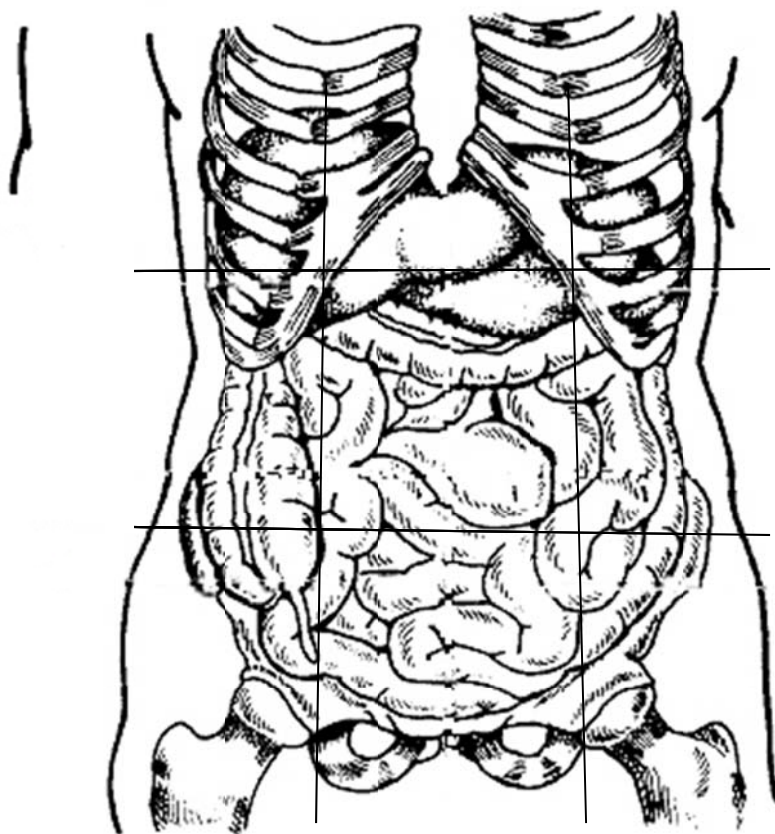


## Color the Abdominal Regions

A. Color the following drawing using the body regions:

1. Right iliac- purple
2. Epigastric- red
3. Left lumbar- blue
4. Right hypochondriac- yellow
5. Umbilical- orange
6. Left iliac- pink
7. Right lumbar-green
8. Hypogastric- brown
9. Left hypochondriac- leave blank

B. Using a black marker label the 4 abdominal quadrants.



## Body Planes and Directions Activity

Planes and directions are practiced using fruit and toothpicks.

Be careful with the surgical instruments. Read and follow the instructions very carefully.

### **Materials:**

Knives

Marker

Colored toothpicks

Bananas

Rulers

### **Banana:**

Cut the banana with a transverse plane. Stick a blue toothpick in the superior end of the banana. Place red toothpick in the most distal point on the right inferior piece. Make a 3cm midsagittal incision on the posterior inferior portion of your banana. Place a yellow toothpick at the anterior superior medial section of the banana. With a marker place a (X) on the left posterior superior lateral section on your banana.

## Short Story

Incorporate the following terms into a story describing your describing your worst nightmare. Underline the term(s) in the story.

Superior  
Inferior  
Anterior  
Abdominal Cavity  
Dorsal  
Pelvic Cavity  
Medial  
Oral Cavity  
Lateral  
Proximal  
Distal  
Superficial  
Deep  
Skeletal System  
Cardiovascular System

## Body Orientation Quiz

1. Describe how a body would be divided by each of the following types of planes:

- A. Frontal (Coronal)
- B. Midsagittal
- C. Sagittal
- D. Transverse

2. Identify the correct directional term to complete the following statements.

- A. The liver is \_\_\_\_\_ to the diaphragm.
- B. Fingers are located \_\_\_\_\_ to the wrist bones.
- C. The skin on the dorsal surface of your body is said to be located on your \_\_\_\_\_ surface.
- D. The great (big) toe is \_\_\_\_\_ to the little toe.
- E. The skin on your leg is \_\_\_\_\_ to the muscle tissue in your leg.
- F. When you float face down in a pool, you are lying on your \_\_\_\_\_ surface.
- G. The lungs and the heart are located \_\_\_\_\_ to the abdominal organs.

3. Identify which cavity each of the following organs are in:

- |                      |                          |
|----------------------|--------------------------|
| A. Heart _____       | G. Lungs _____           |
| B. Liver _____       | H. Spleen _____          |
| C. Intestines _____  | I. Kidneys _____         |
| D. Spinal Cord _____ | J. Stomach _____         |
| E. Brain _____       | K. Urinary Bladder _____ |
| F. Sex Organs _____  | L. Pancreas _____        |

4. Fill in the blank completing the analogy.

- A. anterior is to ventral as posterior is to \_\_\_\_\_
- B. superficial is to external as deep is to \_\_\_\_\_
- C. cranial is to caudal as superior is to \_\_\_\_\_
- D. medial is to lateral as proximal is to \_\_\_\_\_

5. Match the organs with the cavity they are in.

CAVITY

1. \_\_\_\_ cranial cavity
2. \_\_\_\_ spinal cavity
3. \_\_\_\_ thoracic cavity
4. \_\_\_\_ abdominal cavity
5. \_\_\_\_ pelvic cavity

ORGAN

- A. stomach
- B. reproductive organs
- C. brain
- D. small intestines
- E. urinary bladder
- F. spinal cord
- G. liver, gallbladder, pancreas  
and spleen
- H. lung

6. Match the abdominal region with the descriptive term:

1. \_\_\_\_\_ Iliac/inguinal
2. \_\_\_\_\_ Epigastric
3. \_\_\_\_\_ Lumbar/lateral
4. \_\_\_\_\_ hypochondriac
5. \_\_\_\_\_ Umbilical
6. \_\_\_\_\_ hypogastric/ pelvic

- A. above the stomach
- B. near the belly button
- C. below the stomach
- D. below the ribs
- E. near the large bones of spinal cord
- F. near the groin

("Medical anatomy and," 2005)

## Quiz Key

1. Describe how a body would be divided by each of the following types of planes:

- A. Frontal (coronal) - **divides body into anterior and posterior sections.**
- B. Midsagittal - **divides body into equal right and left sides.**
- C. Sagittal - **divides body into right and left sides.**
- D. Transverse - **divides body into superior and inferior sections.**

2. Identify the correct directional term to complete the following statements.

- A. The liver is **inferior** to the diaphragm
- B. Fingers are located **distal** to the wrist bones.
- C. The skin on the dorsal surface of your body is said to be located on your **posterior** surface.
- D. The great(big) toe is **medial** to the little toe.
- E. The skin on your leg is **superficial** to the muscle tissue in your leg.
- F. When you float face down in a pool, you are lying on your **anterior** surface.
- G. The lungs and the heart are located **superior** to the abdominal organs.

3. Identify which cavity each of the following organs are in:

- |                                     |                                  |
|-------------------------------------|----------------------------------|
| A. Heart <b>ventral/mediastinal</b> | G. Lungs <b>ventral/pleural</b>  |
| B. Liver <b>abdominal</b>           | H. Spleen <b>abdominal</b>       |
| C. Intestines <b>abdominal</b>      | I. Kidneys <b>abdominal</b>      |
| D. Spinal Cord <b>vertebral</b>     | J. Stomach <b>abdominal</b>      |
| E. Brain <b>cranial</b>             | K. Urinary Bladder <b>pelvic</b> |
| F. Sex Organs <b>pelvic</b>         | L. Pancreas- <b>abdominal</b>    |

4. Fill in the blank completing the analogy.

- A. anterior is to ventral as posterior is to **dorsal**
- B. superficial is to external as deep is to **internal**
- C. cranial is to caudal as superior is to **inferior**
- D. medial is to lateral as proximal is to **distal**

5. Match the organs with the cavity they are in.

CAVITY

- 1. **C** cranial cavity
- 2. **F** spinal cavity
- 3. **H** thoracic cavity
- 4. **A, D, G** abdominal cavity
- 5. **B, E** pelvic cavity

ORGAN

- A. stomach
- B. reproductive organs
- C. brain
- D. small intestines
- E. urinary bladder
- F. spinal cord
- G. liver, gallbladder, pancreas and spleen
- H. lung

6. Match the abdominal region with the descriptive term:

1.   **F**   Iliac/inguinal
2.   **A**   Epigastric
3.   **E**   Lumbar/lateral
4.   **D**   hypochondriac
5.   **B**   Umbilical
6.   **C**   hypogastric/ pelvic

- A. above the stomach
- B. near the belly button
- C. below the stomach
- D. below the ribs
- E. near the large bones of spinal cord
- F. near the groin

("Medical Anatomy and," 2005)